

HAEMATOLOGICAL CHANGES INDUCED IN LABORATORY RATS BY LARVAL *AMPLICAECUM ROBERTSI* SPRENT & MINES

By C. DOBSON*

[Manuscript received September 13, 1967]

Summary

The pathological effects of *A. robertsi* in the rat were studied for a period of 13 weeks. The acute stage of the disease was characterized by an enlarged and haemorrhagic liver. The chronic phase was associated with enlargement of the liver, liver cirrhosis, anaemia, and serum disturbances.

The progressive development of anaemia was indicative of haemorrhage and the cell picture indicated a macrocytic-normochromic anaemia. This was accounted for by regenerative changes in the blood since large numbers of reticulocytes were found. Some abnormally high mean cell haemoglobin concentration values indicated haemolysis which could be associated with either the toxic and digestive effects of the parasite or immune haemolysis.

There was a general loss of circulating white cells during the acute stage of the infection. This was related to the inflammatory changes which had occurred in the liver. Later in the infection there was a compensatory leucopoiesis which could be associated with the immune responses of the host.

Basophil leucocytes decreased at first and then showed a rapid increase. Changes of this type have been related to allergic reactions and the disruption of tissue mast cells. An eosinophilia occurred which followed the same pattern as the basophil leucocyte response and may also have been due to allergic reactions against the parasite.

Changes in the circulating neutrophil leucocyte and monocyte counts could be correlated with the inflammatory responses against the invading nematode and subsequently with the degenerative changes which occurred in the parasitized liver parenchyma. The increases in circulating lymphocytes and tissue plasma cells were related to the immune reactions against the parasite.

I. INTRODUCTION

Harris (1963) stated that despite considerable variations in the pathogenic and aetiological processes that give rise to chronic liver disease, the associated anaemias usually have similar morphological and patho-physiological characters. Evidence concerning the anaemias occurring during helminth infections of the liver would also support this statement provided allowances are made for the feeding habits of the helminths and the haemorrhages caused by their migration through the liver parenchyma.

Amplicaecum robertsi Sprent & Mines, 1960, is an ascaridoid nematode which spends most of its parasitic life as a larva within the liver of an intermediate host, usually a rodent, and matures in the carpet snake, *Morelia spilotes variegata* (Sprent 1963). The present investigation is a study of the haematological changes and associated liver damage in the rat caused by *A. robertsi*.

* Department of Parasitology, University of Queensland, St. Lucia, Qld. 4067.

II. MATERIALS AND METHODS

Infective eggs of *A. robertsi* were cultured in moist charcoal (Sprent 1963) and the dose calculated by making numerous counts and then diluting the stock suspension of eggs (Dobson 1965).

All the Sprague-Dawley rats used were from a small, randomly mated, helminth-free colony. The rats were 5 months old when infected with 500 *A. robertsi* eggs by stomach tube and maintained under uniform conditions of light, temperature, and humidity in steel boxes on wood litter; food in pellet form and water were available at all times.

Blood samples were taken at 9 a.m. every other day from rats which were used to being handled; aliquots of approximately 0.5 ml were collected from the tail of the rat into Perspex haemagglutination trays to which 0.05 ml EDTA (disodium salt, 20 mg/ml) had previously been added and evaporated to dryness.

Haematocrits were done using microhaematocrit tubes spun at 14,000 r.p.m. for 8 min; further centrifugation did not alter the value obtained [=packed cell volume (P.C.V.)]. Haemoglobin concentrations were measured using an alkaline-haematin method with a Beckman DU spectrophotometer previously calibrated with a haemoglobin standard.

Red cell counts were made using a Neubauer chamber according to the technique in Dacie (1958). Total leucocyte counts were made using the total-dilution method (Dacie 1958). Differential leucocyte counts were made on blood films stained with Giemsa (Dacie 1958); cell differentiation was made after a total of 400 cells had been counted. The cells were divided into five categories, namely monocytes, basophil, neutrophil, and eosinophil leucocytes, and lymphocytes (Wintrobe 1961). All counts were made by selecting random fields around the whole smear. Percentage reticulocyte counts were made from smears stained with new methylene blue (Schalm 1965). The mean cell volume (M.C.V.), mean cell haemoglobin (M.C.H.), and mean cell haemoglobin concentration (M.C.H.C.) were calculated from the formulae given in Dacie (1958).

All the experimental data were obtained from 16 infected and 8 non-infected rats. Individual values were averaged for each week and group means were calculated from these values. These means, together with the standard error of the mean, were graphed against time. The calculated values for M.C.V., M.C.H., and M.C.H.C. were treated in the same way (Figs. 1-13). A statistical analysis of the differences between non-infected and infected rats was done at the first, fourth, and thirteenth week following infection using Student's *t*-test. The values for *t* are given in Table 1 and their corresponding *P* values are given in the text.

III. RESULTS

(a) Gross Observations

In the early stages of larval migration, the liver was enlarged and haemorrhagic and fibrinous clots were seen on the surface. The pathology of the infection depended largely on the number of larvae which invaded the liver: with 500 infective eggs the rats rarely died in the acute stages of the disease; usually they showed increasing lassitude over a period of months until eventually they became recumbent and died 3-4 months after infection.

The chronic disease was associated with cirrhosis and enlargement of the liver. The liver parenchyma was fibrotic and hard and often took on a greyish red colour. The growing larvae often protruded from the liver tissue and frequently came to lie free in the peritoneal cavity. Those larvae which remained within the liver tissue were encapsulated by fibrous tissue. There was always an extensive infiltration of the parasitized tissue by eosinophil leucocytes and lymphocytes. After infection for

3 months the rats often produced large quantities of ascitic fluid which caused gross distention of the abdomen.

(b) *Haematology*

(i) *Red Blood Cells*

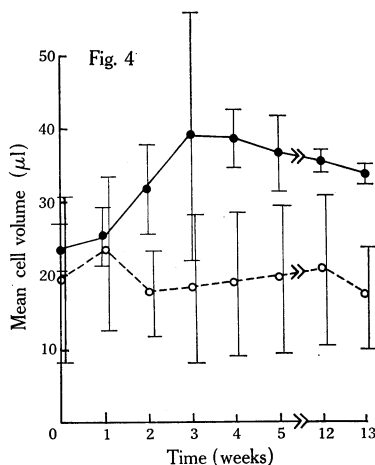
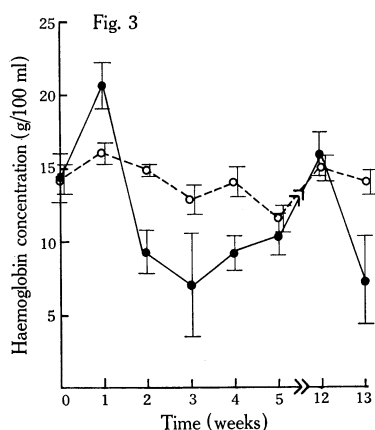
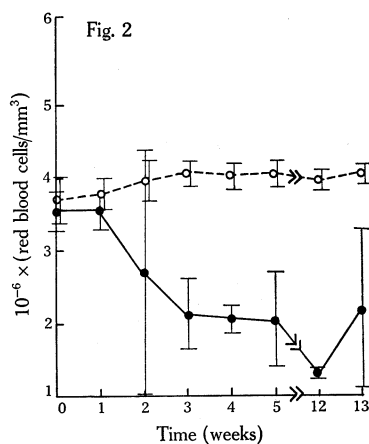
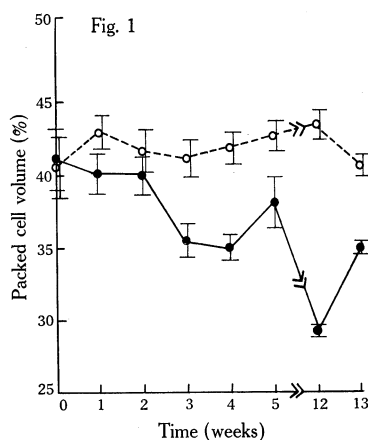
Haemoglobin concentrations increased throughout the first week of infection and then decreased. Loss of haemoglobin occurred between the second and fifth weeks ($P < 0.05$) but there was no difference between the infected and control groups

TABLE 1
ANALYSIS OF HAEMATOLOGICAL DATA FROM 8 NON-INFECTED (C) RATS AND 16 RATS INFECTED
(I) WITH *A. ROBERTSI*

		Rats infected 1 week			Rats infected 4 weeks			Rats infected 13 weeks		
		Mean	±S.E.	<i>t</i>	Mean	±S.E.	<i>t</i>	Mean	±S.E.	<i>t</i>
Packed cell volume (%)	C	43.0	± 1.0	1.04	41.9	± 1.1	4.3	40.3	± 1.0	4.7
	I	40.2	± 1.3		35.0	± 9.1		35.0	± 0.4	
Haemoglobin concn. (g/100 ml)	C	16.1	± 0.3	6.3	15.6	± 0.4	11.6	15.7	± 0.3	3.4
	I	17.0	± 0.5		13.7	± 0.5		12.9	± 1.3	
$10^{-6} \times$ red cells/mm ³	C	5.8	± 0.2	0.8	6.0	± 0.2	6.7	6.0	± 0.1	2.3
	I	5.5	± 0.3		4.1	± 0.2		4.2	± 1.1	
Mean cell volume (μl)	C	73.2	± 10.5	0.2	68.8	± 9.9	2.2	66.7	± 6.7	2.0
	I	75.3	± 4.1		88.5	± 3.9		83.9	± 1.6	
Mean cell haemoglobin (pg)	C	28.6	± 1.0	1.6	26.3	± 0.9	3.5	27.1	± 0.6	1.5
	I	35.2	± 2.5		34.0	± 1.5		30.9	± 1.0	
Mean cell haemoglobin concn. (%)	C	37.8	± 1.1	1.9	36.8	± 1.5	1.2	37.2	± 1.1	0.2
	I	46.8	± 2.8		36.6	± 0.8		36.7	± 1.2	
$10^{-3} \times$ total leucocytes /mm ³	C	13.8	± 0.8	26.8	13.0	± 0.5	3.9	13.1	± 0.9	2.5
	I	11.7	± 0.9		18.8	± 1.0		16.1	± 0.7	
Basophil leucocytes /mm ³	C	68.0	± 14.4	2.5	26.0	± 13.0	5.1	44.0	± 13.4	3.7
	I	23.1	± 10.0		248.4	± 30.6		162.3	± 38	
Monocytes/mm ³	C	440.0	± 23.5	2.5	303.0	± 37.5	2.7	333.0	± 30.3	3.1
	I	304.1	± 55.0		538.0	± 60.0		603.1	± 115.0	
Eosinophil leucocytes /mm ³	C	245.0	± 31.0	2.4	228.0	± 38.0	5.9	248.0	± 35.9	8.6
	I	446.4	± 57.0		1812.0	± 207.0		1787.0	± 268	
Neutrophil leucocytes/mm ³	C	2576	± 289	5.3	2510	± 198	1.8	2547	± 192	0.2
	I	1783	± 204		3376	± 336		2481	± 496	
Reticulocytes (%)	C	2.0	± 0.5	0.7	1.7	± 0.1	3.1	1.5	± 0.1	10.0
	I	2.3	± 0.3		4.2	± 0.8		14.7	± 1.2	

at the fifth and twelfth weeks ($P < 0.05$). At the thirteenth week there was less circulating haemoglobin in infected rats than in the controls ($P < 0.05$). The haemoglobin values of the control rats did not change significantly ($P > 0.05$) over the period of the observations (Fig. 3; Table 1). Both red blood cell counts and P.C.V. decreased from the first day of the infection although the decrease was only significant from the third week ($P < 0.001$). There were no significant changes ($P > 0.05$) in the red blood cell counts or in the P.C.V. values of the control rats throughout the experiment (Figs. 1 and 2; Table 1). However, while there was a decrease in the red blood cell count, the numbers of circulating reticulocytes increased ($P < 0.001$) (Fig. 7; Table 1).

M.C.V. and M.C.H. values increased throughout the infection ($P < 0.05$). However, while the overall M.C.H.C. value did not change during the infection some of the values were significantly greater than those of the controls (Figs. 4, 5, and 6; Table 1). There was no change in M.C.V., M.C.H., or M.C.H.C. values for the control rats over the period of the observations ($P > 0.05$).



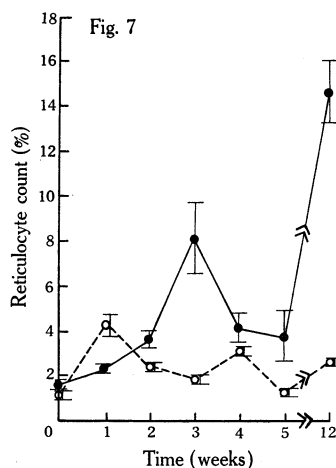
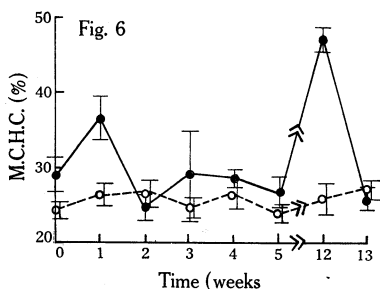
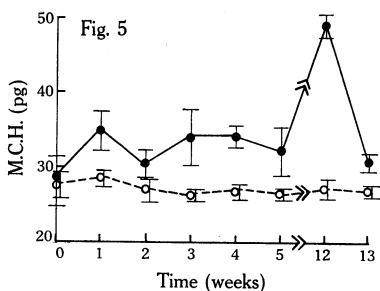
Figs. 1-4.—Changes in the packed cell volume (Fig. 1), red blood cell count (Fig. 2), haemoglobin concentration (Fig. 3), and mean cell volume (Fig. 4) of 16 rats given 500 infective *A. robertsi* eggs (●). ○ Results for 8 non-infected rats.

(ii) White Blood Cells

During the first 7 days of the infection there was a large decrease in the number of white blood cells ($P < 0.001$). By the tenth day, however, this loss had been compensated for and the numbers of circulating white cells then increased, reaching a peak by the fourth week. After 13 weeks of infection, white cell numbers were still

elevated ($P < 0.01$). There was no significant change ($P > 0.05$) in total white cell counts of the control rats (Fig. 8; Table 1).

After an initial decrease in basophil leucocyte counts during the first week of infection ($P < 0.001$), there was an increase until by the fourth week it was 150% higher than in the controls ($P < 0.01$). These counts were still elevated at the thirteenth week of infection ($P < 0.01$), although they were lower than at the fourth week. There was no significant change ($P > 0.05$) in the basophil leucocyte counts of the control rats (Fig. 9; Table 1).



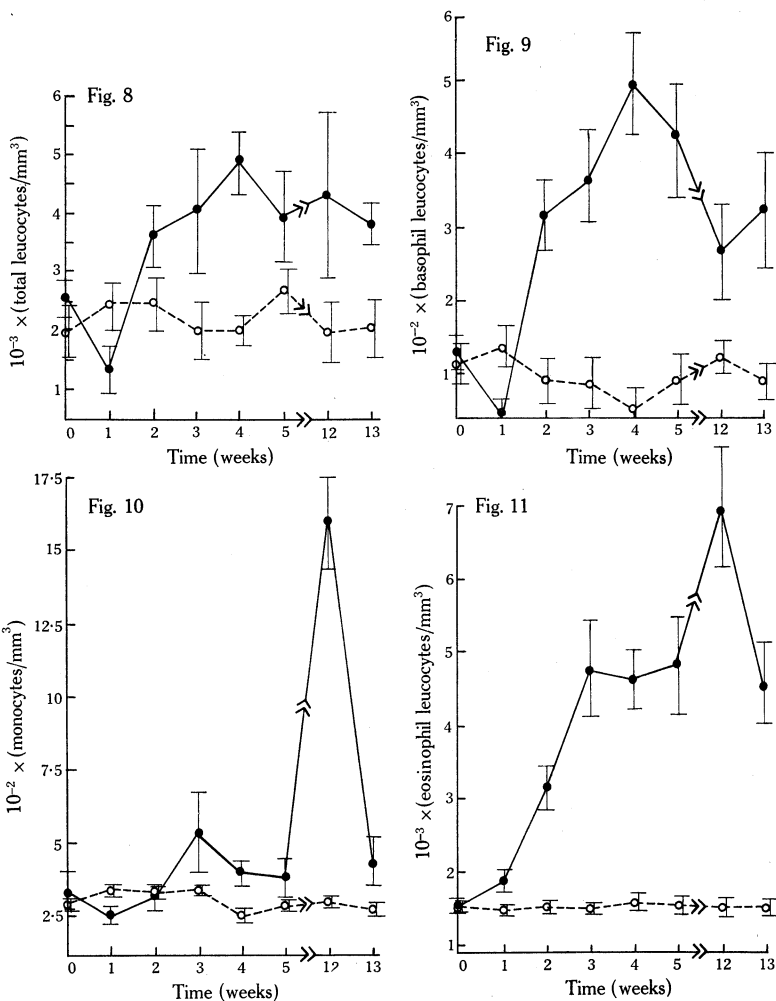
Figs. 5-7.—Changes in the mean cell haemoglobin (M.C.H.) (Fig. 5), mean cell haemoglobin concentration (M.C.H.C.) (Fig. 6), and reticulocyte percentage (Fig. 7) of 16 rats given 500 infective *A. robertsi* eggs (●). ○ Results for 8 non-infected rats.

Monocyte counts decreased after 1 week of infection ($P < 0.01$), and then increased until by the third week they were greater than in the controls; the counts continued ($P < 0.01$) at this elevated level for the rest of the observations (Fig. 10; Table 1). There was no significant change ($P > 0.05$) in the monocyte counts of the control animals (Fig. 10; Table 1).

Eosinophil leucocyte numbers first decreased and then rapidly increased, reaching a peak by the third week of infection ($P < 0.001$); the initial loss of circulating cells is not shown in the graph because the data for the week was averaged. The counts then remained at this high level for the rest of the infection without any significant change ($P > 0.05$). There was no significant change ($P > 0.05$) in the eosinophil leucocyte counts of the control rats (Fig. 11; Table 1).

Neutrophil leucocytes decreased in numbers during the first week of infection ($P < 0.05$), and then increased until there were significantly more in the infected

than in the control rats during the third and fourth weeks following infection ($P < 0.05$). However, after this period there was no difference ($P > 0.05$) between the counts from each group (Fig. 12; Table 1).

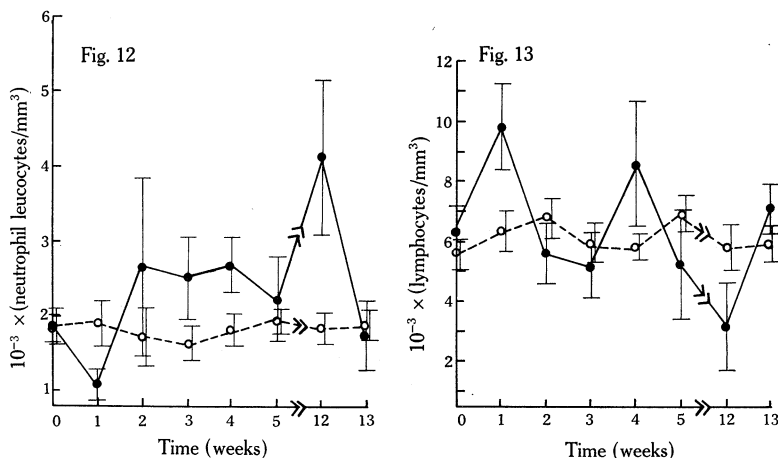


Figs. 8-11.—Changes in the total leucocyte count (Fig. 8), the basophil leucocyte count (Fig. 9), the monocyte (Fig. 10), and the eosinophil leucocyte count (Fig. 11) of 16 rats given 500 infective *A. robertsi* eggs (●). ○ Results for 8 non-infected rats.

Lymphocyte counts of the infected rats were erratic and while some points were greater than the controls others were less; the overall picture did not significantly change ($P > 0.05$). There was no significant change ($P > 0.05$) in the control lymphocyte counts (Fig. 13; Table 1).

IV. DISCUSSION

In rats infected with *A. robertsi* an anaemia developed which initially was normocytic but became progressively macrocytic in nature. This effect was directly related to an increase in the circulating reticulocytes which became significant at the second week of infection. Increases in M.C.H. values could also be related to reticulocytosis. Harris (1963) pointed out that changes of this nature were usually associated with liver damage and that the degree of anaemia was directly proportional to the extent of liver damage.



Figs. 12–13.—Changes in the neutrophil leucocyte count (Fig. 12) and lymphocyte counts of 16 rats given 500 infective *A. robertsi* eggs (●). ○ Results for 8 non-infected rats.

The gross pathology of the liver of infected rats closely resembles changes in sheep liver after infection with *Fasciola hepatica*. In the latter case an anaemia develops which is of the normocytic–normochromic type (Sinclair 1962). This anaemia is usually associated with the feeding habits of the adult liver fluke (Stephenson 1947; Jennings, Mulligan, and Urquhart 1956) and with the arrival of flukes within the bile ducts (Sinclair 1962). At this time there also developed a hypoalbuminaemia in the infected animals. Similar effects can be shown in rats infected with *A. robertsi*, and they also appear to be related to the arrival of larval *A. robertsi* in the liver, at which time the anaemia occurred and a hypoalbuminaemia began to develop (Dobson, unpublished data). Sinclair (1962) further associated the anaemia caused by *F. hepatica* with haemorrhage and as he was unable to demonstrate circulating regenerative forms of these erythrocytes, which might be expected during compensatory erythropoiesis, he related (1964) this anaemia to loss of erythropoietic function and shortening of the life span of the red blood cells as well. However, Grunsell (1955) has pointed out that regeneration of red cells in sheep is mostly confined to the bone marrow and that reticulocytes are rarely seen in the circulation. The anaemia caused by *A. robertsi* was very similar to that caused by

F. hepatica since it was of the regenerative haemorrhagic type. However, the cell picture indicated a macrocytic-normochromic anaemia; this increased cell size was expected in view of the large proportions of circulating reticulocytes.

Although the progressive development of the anaemia in infected rats was indicative of haemorrhage, certain inconsistent changes occurred in the M.C.H.C. Schalm (1965) pointed out that if the M.C.H.C. exceeded 35% an abnormal change had occurred, since the haemoglobin can only occupy this proportion of the erythrocyte. The high values for M.C.H.C. noted during these experiments thus indicated that a significant proportion of the haemoglobin was free in the plasma. Haemolysis may be associated with two phenomena resulting from the infection. Firstly, the feeding of the nematode lysed the cells either by digestion or by the effects of toxic substance, and secondly, immune haemolysis may have occurred. Soulsby and Coombs (1959) suggested that immune haemolysis could be associated with certain helminth immunities. In the case of *A. robertsi* in the rat, immune haemolysis may be related to the anaphylactic reactions which occur in the infected liver (Dobson, unpublished data). Sinclair (1964) has stated that the haemorrhagic anaemia of ovine fascioliasis was related to degenerative changes in the red cell as well as to blood loss. He associated these degenerative effects with the loss of serum proteins produced by disturbances in protein metabolism occurring during infection. There may be a similar effect on the red cells of the rat infected with *A. robertsi*.

Interest in the circulating white cell populations of helminth-infected animals has mainly been centred on the development of allergic eosinophilias (Wintrobe 1961; Gross 1962; Archer 1963; Zaiman *et al.* 1963; Archer *et al.* 1966). Nevertheless, there are equally interesting changes which take place in other specific cell populations of the blood.

There was a general loss of white cells from the circulation of the rat during the first 10 days of infection. This loss could be correlated with the inflammatory changes which occurred in the infected liver where, after 4 days infection, there was an infiltration of large numbers of neutrophil leucocytes and monocytes. From the fifth day of infection there was also a steady increase in the number of tissue eosinophil leucocytes and mast cells (Dobson, unpublished data). After the tenth day of infection the total white cell count increased throughout the rest of the period of infection observed. This increase was associated with compensatory leucopoiesis and the immunological responses of the host.

The circulating basophil leucocyte count decreased during the acute phase of the infection but thereafter increased as the disease became chronic. Braunsteiner and Thumb (1958a, 1958b) showed a similar relationship between allergic disease and the peripheral basophil leucocyte count. These reactions may also be related to the mast cell changes which occurred within the infected tissue (Dobson, unpublished results). Braunsteiner (1962) further demonstrated that there was at least a functional if not ontological relationship between mast cells and basophil leucocytes. Therefore it is reasonable to relate the increase in tissue mast cells, during the acute stage of the infection, with the loss of basophil leucocytes from the blood. The stimulus causing the subsequent proliferation of the circulating basophil leucocytes may

originate in the disruption of mast cells during the allergic reactions (Briggs 1963*a*, 1963*b*).

Eosinophilia and mast cell proliferations have often been associated with helminth infections. However, in the case of *A. robertsi*, Archer *et al.* (1966) showed that proliferation of eosinophil leucocytes was not associated with an increase in serum histamine levels which suggests that mast cells were not associated with the eosinophilia. Nevertheless, Archer (1963) demonstrated a relationship between serum histamine levels and eosinophilia in horses, while Wells (1962) demonstrated that with *Nippostrongylus braziliensis* infections in rats tissue eosinophilia was associated with mast cell proliferation and increased levels of tissue histamine. Thus, in *A. robertsi* infections, an increase in histamine may have been localized only in the infected tissue where mast cell disruption and increasing eosinophilia can be demonstrated (Dobson, unpublished results). The eosinophilic reaction noted during these experiments was the same as that outlined by Gross (1962) where there was an initial loss of peripheral eosinophil leucocytes followed by an overcompensating increase in numbers; the rate of increase then moderated, but still continued. Archer *et al.* (1966) showed that the maximum increase in eosinophilia occurred by the eighteenth day of infection. In the present experiments the maximum occurred 3 weeks after infection. While eosinophilia can be definitely associated with allergic reactions the cause of the response is not known. It has often been stated that eosinophilia occurs in response to antigen-antibody reactions (Litt 1962) but early work by Campbell, Drennan, and Rettie (1935), Campbell (1940, 1943), Studer and Fast (1951), and Vaughn (1952, 1953) showed that *Ascaris* preparations stimulated eosinophilias after injection into non-sensitized guinea-pigs. Also Archer *et al.* (1966) demonstrated eosinophil leucocytes in the portal veins of rats 3 days after infection, and suggested that natural antibodies were involved, but Schmidt (1949) has shown that while the fats of *Ascaris lumbricoides* failed to act as antigens, they stimulated eosinophilia. On the other hand, the association of eosinophil leucocytes with anaphylactic reactions may be correlated with the removal of histamine from the lesion although the presence of histamine may not have caused the original aggregation at the site (Samter 1949; Litt 1960).

Both the circulating neutrophil leucocyte and monocyte counts showed a transient loss followed by an increase in numbers in the blood after infection. Both these effects occurred at the time inflammatory changes were most evident in the infected liver. The initial loss of cells from the circulation was related to the acute inflammation of the liver, and the neutrophilia and monocytosis to the chronic necrotic changes in the liver parenchymal cells.

Traumatic and haemorrhagic hepatitis have been associated with acute hepatic cysticercosis in sheep, calves, and pigs (Soulsby 1965) and also in sheep with acute fascioliasis (Marek 1927; Taylor 1951; Sinclair 1962). These infections lead to enlargement and damage of the liver, biliary cirrhosis, and haemorrhage. The animal may die but if it does not the chronic disease may be associated with extensive biliary cirrhosis and the development of anaemia and serum disturbances (Stephenson 1947; Jennings, Mulligan, and Urquhart 1956; Urquhart 1956; Sinclair 1962).

In conclusion, *A. robertsi* infections in rats give rise to cirrhosis of the liver and an associated anaemia which is probably both haemorrhagic and haemolytic in origin. The white cell responses of the host, particularly the eosinophilia, are typical of those occurring during inflammation and allergic reactions.

V. ACKNOWLEDGMENTS

This work was supported by a grant from the Australian Wool Board. I should like to thank Professor J. F. A. Sprent for his continued interest in this work and Miss R. Heffernan for her conscientious assistance.

VI. REFERENCES

- ARCHER, R. K. (1963).—"The Eosinophil Leucocytes." (Blackwell Scientific Publications: Oxford.)
- ARCHER, G. T., BARKER, A., AIR, G., and MCGOVERN, V. J. (1966).—*Aust. J. exp. Biol. med. Sci.* **44**, 45.
- BRAUNSTEINER, H. (1962).—In "The Physiology and Pathology of Leucocytes". (Eds. H. Braunsteiner and D. Zucker-Franklin.) (Grune and Stratton: New York.)
- BRAUNSTEINER, H., and THUMB, N. (1958a).—*Wien. Z. inn. Med.* **39**, 285.
- BRAUNSTEINER, H., and THUMB, N. (1958b).—*Acta haemat.* **20**, 339.
- BRIGGS, N. T. (1963a).—*Ann. N.Y. Acad. Sci.* **113**, 456.
- BRIGGS, N. T. (1963b).—*J. infect. Dis.* **113**, 22.
- CAMPBELL, A. C. P., DRENNAN, A. M., and RETTIE, T. (1935).—*J. Path. Bact.* **40**, 537.
- CAMPBELL, D. H. (1940).—*J. infect. Dis.* **71**, 270.
- CAMPBELL, D. H. (1943).—*J. infect. Dis.* **72**, 42.
- DACIE, J. V. (1958).—"Practical Haematology." (J. and A. Churchill Ltd.: London.)
- DOBSON, C. (1965).—*Parasitology* **55**, 183.
- GROSS, R. (1962).—In "The Physiology and Pathology of Leucocytes". (Eds. H. Braunsteiner and D. Zucker-Franklin.) (Grune and Stratton: New York.)
- GRUNSELL, C. S. (1955).—*J. comp. Path. Ther.* **65**, 8.
- HARRIS, J. W. (1963).—"The Red Cell." (Harvard University Press: Cambridge, Mass.)
- JENNINGS, F. W., MULLIGAN, W., and URQUHART, G. M. (1956).—*Expl Parasit.* **5**, 458.
- LITT, M. (1960).—*Blood* **16**, 1330.
- LITT, M. (1962).—*J. Allergy* **33**, 532.
- MAREK, J. (1927).—*Dt. tierärztl. Wschr.* **35**, 513.
- SAMTER, M. (1949).—*Blood* **4**, 217.
- SCHALM, O. W. (1965).—"Veterinary Haematology." 2nd Ed. (Lea and Febiger: Philadelphia.)
- SCHMIDT, H. (1949).—*Zentbl. Bakt. Parasitkde* **154**, 139.
- SINCLAIR, K. B. (1962).—*Br. vet. J.* **118**, 37.
- SINCLAIR, K. B. (1964).—*Br. vet. J.* **120**, 212.
- SOULSBY, E. J. L. (1965).—"Textbook of Veterinary Clinical Parasitology." Vol. 1. Helminths. (Blackwell Scientific Publications: Oxford.)
- SOULSBY, E. J. L., and COOMBS, R. R. A. (1959).—*Parasitology* **49**, 505.
- SPRENT, J. F. A. (1963).—*Parasitology* **53**, 7.
- STEPHENSON, W. (1947).—*Parasitology* **38**, 123.
- STUDER, A., and FAST, B. (1951).—*Z. Hyg. InfektKrank.* **133**, 327.
- TAYLOR, E. L. (1951).—*Vet. Rec.* **63**, 859.
- URQUHART, G. M. (1956).—*J. Path. Bact.* **71**, 301.
- VAUGHN, J. (1952).—*J. Path. Bact.* **64**, 91.
- VAUGHN, J. (1953).—*Blood* **8**, 1.
- WELLS, P. D. (1962).—*Expl Parasit.* **12**, 82.
- WINTROBE, M. M. (1961).—"Clinical Haematology." 4th Ed. (Lea and Febiger: Philadelphia.)
- ZAIMAN, H., SCARDINO, V., BERSON, P., and STERN, R. C. (1963).—*Expl Parasit.* **14**, 1.